

the ovaries. Also, systemic administration eliminates the risk of damage to the endometrium. Repeated treatment can be carried out relatively simple and without introduction of new infections. Because there are reasons to assume that a moderate to severe uterine infection seldom localized only to the superficial layer of the endometrium, therapeutic plans would have to consider systemic treatment. Several antibiotics are inappropriate for the treatment of uterine infections. Nitrofurazone is an irritant and has adverse effect on fertility. Aminoglycosides are not effective in the predominantly anaerobic environment of the infected uterus. Sulphonamides are ineffective because of the presence of para-aminobenzoic acid metabolites in the lumen of the infected uterus.

Broad spectrum antibiotics such as oxytetracycline used at a dose rate up to 22 mg/kg body weight will provide effective minimal inhibitory concentrations in the lumen and uterine tissues. Systemic administration of penicillin results in genital tract tissue and lumen concentrations similar to blood plasma concentrations in cows. Other antibiotics such as metronidazole, ciprofloxacin and cephalosporin are administered systemically as well as intrauterine for the treatment of uterine infections.

#### Antiseptics

Intrauterine infusions with various antiseptics such as lugol's iodine and povidone iodine are relatively common for treatment for postpartum infections. Because intrauterine use of antiseptics may suppress the uterine defence mechanisms like phagocytosis, the use of intra uterine infusions in the postpartum cow is not recommended.

#### Prostaglandins

When there is a palpable mature corpus luteum on the ovary, one method of treating clinical endometritis is with prostaglandin F 2 alpha. It causes luteolysis thereby reducing high progesterone concentrations, return of estrum and elimination of infections. When the animal comes in estrum it can be additionally treated with antibiotics.

#### Immuno- modulators

##### i) Lipopolysaccharides of E. coli

Serotype 026:B6. Dissolve 100 micro gram in 20 ml phosphate buffered saline and administer on the day of estrum intra uterinely.

##### ii) Oyster glycogen

Migration of WBCs into the uterine lumen of healthy cows is stimulated after intrauterine administration of oyster glycogen, up to 90 % of all cells identified in uterine secretions being neutrophils. Variable concentrations of oyster glycogen between 0.1 to 10 % in 60 ml of saline produced identical responses with peak PMN concentration 12 hours after administration.

##### iii) Leukotrine B4

Leukotrine B4 (LTB4) is an effective chemo-attractant, stimulating preferential migration of PMNs into the lumen of the bovine uterus. A single intrauterine treatment of a 30 nmol/L solution increased the intrauterine leucocyte count 5- 10 times within 24 hours.

##### iv) Autologous plasma

Collect about 100 ml of blood from the estrus animal and separate the plasma. Administer 50 ml of plasma through intrauterine route on days 1, 2 and 3 of estrum.



#### Prepared under Tribal Sub-plan 2011-2012

**Dr. M. Karunakaran**  
Scientist  
(Animal Reproduction)

**Dr. E. B. Chakurkar**  
Senior Scientist  
(Animal Reproduction)

**Dr. P. K. Naik**  
Senior Scientist  
(Animal Nutrition)

**Dr. B. K. Swain**  
Senior Scientist  
(Poultry Science)

**N. P. Singh**  
Director  
(ICAR, RC Goa)

**Published by**  
**N. P. Singh**

Director  
ICAR Research Complex for Goa  
Old Goa, Goa- 403 402

**Technical Assistance**  
**Mr. Sidharth Marathe**  
T-5 (PME Cell)

#### For further details contact

**N. P. Singh**  
Director

ICAR Research Complex for Goa  
Old Goa, Goa- 403 402  
Ph.: (0832) 2284678 / 79

Email: [director@icargoa.res.in](mailto:director@icargoa.res.in) / [www.icargoa.res.in](http://www.icargoa.res.in)

All rights reserved  
©2012, ICAR Research Complex for Goa

# Endometritis in Dairy Cows Causes and Management



**ICAR RESEARCH COMPLEX FOR GOA**  
(Indian Council of Agricultural Research)  
Old Goa - 403 402, Goa

## Endometritis in Dairy Cows Causes and Management

**E**ndometritis is a localized inflammation of uterine wall and usually a cause for bovine infertility. The causal organisms usually reach the uterus at coitus, insemination, parturition and post-partum. The retention of foetal membrane, abortion, dystocia, mounting by infected bull, unhygienic practices at insemination, hypocalcaemia, season and poor nutrition are the main factors associated with the development of endometritis.

### Clinical signs

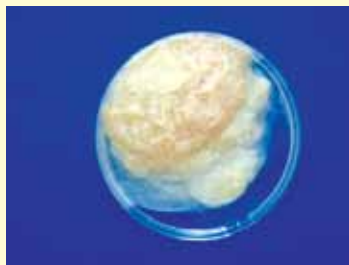The presence of a whitish yellow muco-purulent vaginal discharge is the main clinical sign. Volume of discharge increases at estrus. Cows rarely show systemic illness. On rectal examination thick uterine wall with doughy feel will be noticed.




Vaginal discharge in the affected cow



Vaginal mucus containing flecks of white or off-white pus



Vaginal mucus discharge containing  $\geq 50\%$  purulent material, usually white or yellow, but occasionally sanguineous.



Vaginal mucus containing  $\leq 50\%$  white or off-white purulent material

### Diagnosis

- **History**
- **Rectal examination**
- **Whiteside test**
- **Bacterial culture**
- **Clinical signs**
- **Vaginoscopy**
- **Uterine biopsy**

### Whiteside test

Cervical mucus is collected aseptically and mixed with equal volume of 5 % NaOH in a test tube. The mixture is heated up to the boiling point and the intensity of colour change is graded as

Colour	Degree of endometritis
Turbid	Normal
Light yellow	Mild
Yellow	Moderate
Dark yellow	Severe

### Endometrial biopsy

Relatively easy and safe procedure for the practicing veterinarian to perform. Its use in conjunction with a detailed history, rectal and vaginal examinations and microbial cultures can lead to a more accurate prognosis of difficult breeders and greater therapeutic efficiency. Biopsy lesions heal rapidly and haemorrhages are of little or no clinical significance. Biopsy specimen should be sufficient size (4 x 6 mm). Specimens should be taken from both the uterine horns and body due to variability of pathology in each section. Albuchin's uterine biopsy catheter is used to obtain in vivo uterine endometrial samples.



Uterine biopsy catheter

Proper disinfection and sterilization of the biopsy instrument are necessary to prevent microbial contamination. Before taking biopsy, thoroughly scrub and clean the vulva and perineal area. Evert the vulval lips and introduce the biopsy instrument in closed position through vagina into uterus. Gently push the piston to open the cutting edge. Press a portion of the uterine wall into the cavity of the cutting edge. Pull the piston caudally to close the cutting edge so as to remove a piece of the endometrium. Withdraw the instrument out

of the reproductive tract in closed position. Remove the endometrial tissue from the instrument and immediately transfer it into 10 % neutral buffered formalin solution at room temperature. Tissues are trimmed, dehydrated, cleared and embedded in paraffin sections and cut at a thickness of 5 – 6 micron and stained with haematoxylin and eosin stain for histological examination.

### Interpretation

Bovine endometrium is evaluated histologically for periglandular fibrosis, cystic glandular changes and cellular infiltration of endometrial stroma. Cellular infiltration is most striking feature of acute endometritis. Moderate and severe cases of endometritis are much easier to diagnose on the basis of the increased number of inflammatory cells spread throughout the stratum compactum and spongiosum layers compared with few cells seen in mild endometritis.

Neutrophils may be present in high numbers during normal estrum – erroneously suggesting acute endometritis. Neutrophils present during the luteal phase – definitely indicative of an acute endometritis. Initial phases of endometritis- diffuse and possibly the periglandular and perivascular infiltrations are dominated by neutrophils and lymphocytes.

### Treatment

Many cases of endometritis are self-limiting and resolve after the resumption of estrus cyclicity and sexual rest. Antibiotic therapy, hormones, antiseptics and immune-modulators are the common approach to handle the endometritis.

### Local vs systemic administration

For antimicrobial treatment to be successful, an effective concentration of drug must be achieved and maintained at the site of infection for an adequate period. Several antimicrobial agents are absorbed from the uterus (tetracycline, penicillin, ampicillin and gentamicin). Uterine pathologic changes results in poor absorption and adequate concentrations are not achieved in the sub endometrial tissues, vagina and oviducts.

Systemic administration usually results in uterine tissue and lumen antibiotic concentrations equal to blood plasma concentrations. The concentrations are the same in the normal and pathologic uterus. The systemic administration gives a better distribution in the tubular genital tract and to